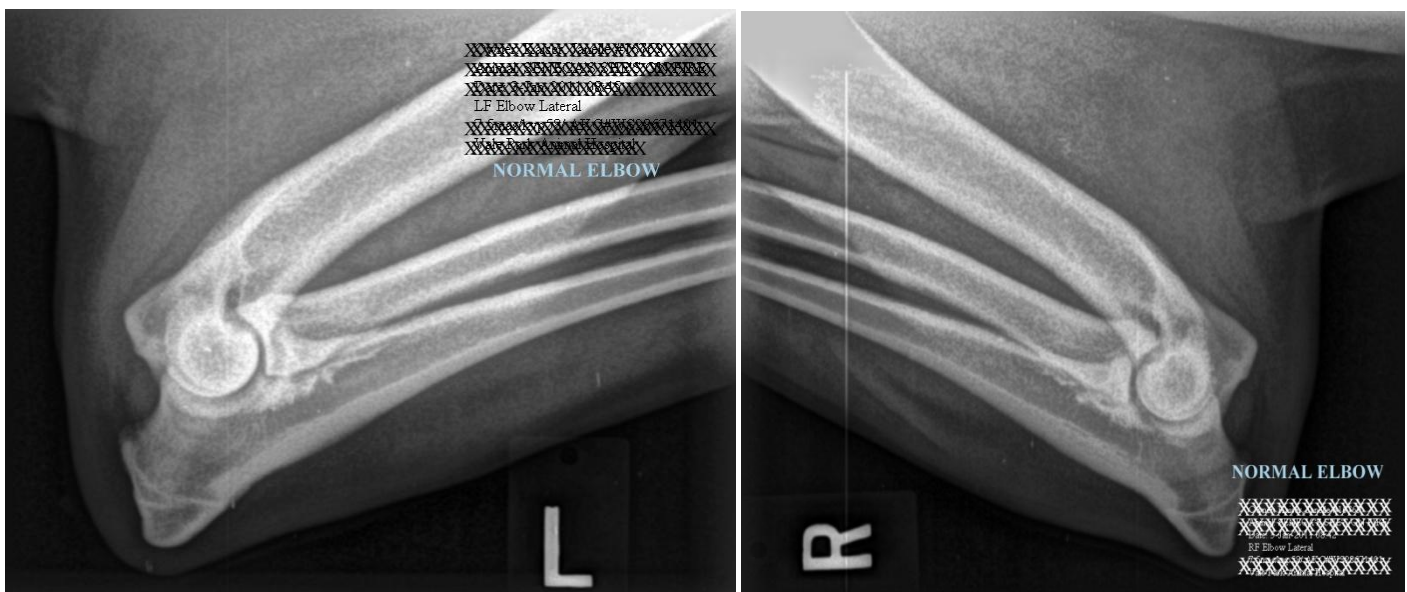


Elbow Dysplasia

Manifested as: OCD, FCP(fragmented coronoid process), UAP (ununited anconeal process), DJD (degenerative joint disease, note that DJD may also occur in the cartilage of other joints). The form most often diagnosed in GSMDs appears to be DJD, a slowly progressive form of cartilage degeneration usually caused by trauma or abnormal wear on the joint. DJD is classified as primary (idiopathic or no known cause) or secondary (a known predisposing cause or injury exists). Anecdotal evidence suggests that most GSMDs diagnosed with DJD during radiographs of the elbows for OFA certification fall into the mildest form grade I. They have never displayed any clinical signs such as pain, stiffness, decreased range of motion or lameness. With DJD, genetic predisposition cannot be established as definitely as with other orthopedic conditions. Hence, there is a wide range of opinions among GSMD breeders with regard to breeding a dog affected with DJD grade I. There is, however, general consensus among breeders not to use GSMDs with DJD beyond grade I as well as with any of the other forms of ED.

Article by Brigitte Rhinehart

[The Three Faces of Elbow Dysplasia by OFA](#)



(examples of left and right Greater Swiss Mountain Dog “Normal” Elbows as rated by OFA)